




2020

Uterine Transplantation: A Review of Some of the Factors that Account for the Success or Failure of this Experimental Procedure

Rachel Stern
Touro College

Follow this and additional works at: <https://touro scholar.touro.edu/sjlcas>

 Part of the [Biology Commons](#), and the [Pharmacology, Toxicology and Environmental Health Commons](#)

Recommended Citation

Stern, R. (2020). Uterine Transplantation: A Review of Some of the Factors that Account for the Success or Failure of this Experimental Procedure. *The Science Journal of the Lander College of Arts and Sciences*, 14(1), 52-58. Retrieved from <https://touro scholar.touro.edu/sjlcas/vol14/iss1/6>

This Article is brought to you for free and open access by the Lander College of Arts and Sciences at Touro Scholar. It has been accepted for inclusion in The Science Journal of the Lander College of Arts and Sciences by an authorized editor of Touro Scholar. For more information, please contact touro.scholar@touro.edu.

Uterine Transplantation: A Review of Some of the Factors that Account for the Success or Failure of this Experimental Procedure

Rachel Stern

Rachel Stern will graduate with an Honors Bachelor of Science degree in Biology in January 2021.

Abstract

Those who suffer from infertility, either due to a congenital or acquired cause and cannot or are opposed to other means, such as surrogacy or adoption, to have a child, are potential candidates for uterine transplantation. Uterine transplantation is a form of allograft transplantation, meaning that it is a transplant of tissue from a donor who is genetically different from the recipient. Additionally, it is a vascularized transplant, including donor blood vessels that will be sutured to the vasculature of the recipient (Testa et al. 2017). This procedure has been attempted around the globe with varying levels of success ranging from delivery of a healthy child to necrosis of the graft and rejection of the transplanted tissue. While there does not seem to be one specific reason that can account for the rejection of a uterus transplant, the main factor responsible for failure is problems with arterial inflow or venous outflow in the recipient. Other potential factors that may contribute include cervix-vaginal size differences between donor uterus and recipient, pathology of the donated uterus, immunosuppressants, and wait time from transplant to embryo transfer. Advancements in robotic assisted hysterectomy to procure the donor uterus, using ovarian veins instead of uterine veins for venous outflow, and deceased donor uteri instead of living donor uteri are all promising ways that can streamline the transplant process and help transition the experimental procedure of uterine transplantation to an accepted clinical one.

Introduction

Uterine transplantation is a procedure where a uterus from either a live or deceased donor is surgically implanted temporarily in a recipient, in order that the recipient can carry her own child in the transplanted uterus. The transplanted uterus is subsequently removed, either when a baby is born, if the pregnancy is terminated due to complications, or due to rejection of the transplant. Uterine Transplantation is an innovative treatment for those who are unable to carry a fetus in their own respective uteri, either due to a congenital disorder, such as the absence of or an underdeveloped uterus, hysterectomy, due to disease, cancer, endometriosis, elective hysterectomy, or for transgender individuals who do not have a uterus (Testa et al., 2017). Since uterine transplantation is not considered a life-saving procedure, many are ethically opposed to the promotion and investment into such an experimental and costly surgery.

In this paper we will try to determine if the uterus can be transplanted successfully with childbearing results, and which factors are responsible for the rejection of a uterus transplant.

Materials and Methods

The Information contained in this review was found by searching the Touro online library general search, Ebsco, and Proquest databases using key terms such as “uterine transplantation.” Pubmed and Google Scholar were also searched utilizing similar key words and phrases.

Candidates for Uterine Transplantation

People who express interest in uterus transplants generally suffer from what is known as uterine factor infertility, UFI (Arian et al., 2017), also known as absolute uterine factor infertility, AUI (Branstrom et al., 2020), This can be

due to a congenital cause, such as a condition known as Mayer-Rokitansky-Kuster-Hauser syndrome (MRKH), or Mullerian agenesis, which is caused by the “underdevelopment of the Mullerian duct, with resultant agenesis or atresia of the vagina, uterus, or both” (Oelschlager, 2018). Aggenesis refers to the failure during embryological development of an organ and atresia is where there is either an obstruction to the lumen, or an opening is abnormally narrowed. Since the Mullerian duct in utero is responsible for the development of the uterus, fallopian tubes, cervix, and the upper part of the vagina, when it fails to develop in MRKH, all those structures, aside from the ovaries, are affected, and this often results in infertility. Patients with MRKH are good candidates for uterine transplantation because they have functioning ovaries, which are not included in the uterus transplant. Their oocytes can be extracted for in vitro fertilization, and they can have a biological child of their own genetics. Another class of those who are interested in uterine transplants include those who have absolute uterine factor infertility due to an acquired cause which resulted in hysterectomy, such as fibroid tumors, endometriosis, chronic pain, abnormal bleeding, malignancy, and obstetric complications. In one study, out of the 239 people screened, one third sought treatment due to congenital UFI, while the other two thirds had acquired UFI. Of the acquired group, half were due to benign conditions, 25.3% were due to gynecologic malignancies, and 24.7% had had prior obstetric complications that resulted in hysterectomy. Although there were five transgender and one intersex individual, they were not included because they did not fit the inclusion criteria of the screening (Arian et al., 2017). In another 2017 study, candidates similarly included those with MRKH, acquired conditions such as irreversible intra-uterine adhesions, fibromas that could not be operated

Uterine Transplantation Factors Accounting for Success or Failure

on, and those who had lost their uterus from either benign or malignant pathologies or postpartum complications (Testa et al., 2017).

Donor Eligibility

Different studies had varied qualifications included in their inclusion criteria. Firstly, age was a consideration. In one study, age was determined to be from 40-60, though those under the age of forty were considered if a candidate had successful pregnancies in the past and did not want to have another pregnancy in the future (Testa et al., 2017). Similarly, in other studies, with successful live-birth outcomes, a 32 year old uterus was used, having borne 2 children prior to transplantation (Testa et al., 2018), and a 24 year old nulligravid uterus was also used in successful transplantation (Chmel et al., 2019). However, in the first successful transplant in 2014 that resulted in childbirth, a 62 year old uterus was used, and another a successful live birth resulted from a 63 year-old uterus at the time of birth, indicating that although older uteri are not necessarily considered ideal, they have yielded live births. (Brannstrom et al., 2020). Since often enough recipient's mothers want to be donors for their daughters, in some studies an older upper limit is given at 55-65 years of age (Kisu et al., 2018).

Additional donor requirements in some studies included criteria such as testing negative for gonorrhea, chlamydia, syphilis and HPV, or previous vaccination against HPV. Previous history of HSV-2 was considered if there were no current symptoms, and previous HPV was considered as long as a negative history was shown since the case of HPV. Last, one prior full-term live birth was a qualification (Testa et al., 2017).

Other requirements included normal-shaped uteri, proper perfusion through uterine vasculature, and the absence of uterine damage or disease (Chmel et al., 2019).

Nulliparous, Nulligravid, or Multiparous Donor Uterus

In choosing between a nulligravid uterus, one that has never carried a fetus, a nulliparous uterus, a uterus that has never born offspring, and a multiparous uterus, one that has born offspring, different studies included multiparity in the inclusion criteria while others did not. According to a 2019 study using a nulliparous deceased donor, nulliparity was considered an advantage in terms of graft recovery because the uterine veins and arteries were straight and not varicose, as opposed to what they noted with multiparous donors (Chmel et al., 2019). However, that was an observation made using few subjects, and would need to be further investigated to determine if a significant difference between the straightness of vasculature exists between nulliparous and multiparous uteri.

Live vs. Deceased Donor

Before investigating the differences between a living as opposed to a deceased donor, it is important to define who is considered "deceased." In this paper, deceased is used to mean brain-dead.

There are certain advantages to using a deceased donor over a live donor. Firstly, using a live donor to procure a graft includes certain risks associated with any surgical procedure, such as the use of anesthesia, and surgery, and specifically possible urological, psychological or sexual dysfunction that may result, which are not considerations that need to be taken with a deceased donor. Secondly more radical surgical dissection can be done using a deceased donor than a live donor, which enables surgeons to procure larger vessels, decreasing the risk of graft thrombosis. Additionally, a longer vaginal cuff can be procured from a deceased donor, allowing a better vaginal-vaginal anastomosis between the donated uterus and the recipient's vagina (Chmel et al., 2019).

A clear disadvantage of using a deceased donor is the practicality; the nature by which deceased donor uteri become available is unpredictable. Also, multidisciplinary teams and the recipient must go to the location of the donor. Moreover, in many countries, physicians have less access to deceased vascularized composite allografts, and there is more restricted access to deceased donor uteri due to the complicated nature of surrogate consent if the deceased has not expressly stated the desire to donate before death (Chmel et al., 2019).

However, new innovations in procurement of the donor uterus, such as using robotically-assisted minimally invasive procedures, can likely decrease risks to live donors by minimizing tissue trauma and bleeding compared to open surgery, which would favor using live donor uteri (Brannstrom et al., 2020). In one minimally invasive, robotic surgery, the estimated blood loss of the donor was 400 mL, compared to the researchers previous surgeries using laparotomy in nine cases, which ranged from estimated blood loss values between 300-2400 mL, with an average of 920 mL (Brannstrom et al., 2020). Using robotic technology can also provide more dexterity and seven degrees of freedom for the surgeon, not to mention micro-suturing can be done more efficiently through laparoscopic ports (Wei et al., 2017). Also, minimally invasive robotic procedures can minimize both surgery and recovery time for the donor (Carbonnel et al., 2020). Surgery time in one robotic assisted surgery took 6 hours, which is the shortest surgery duration time recorded for uterus procurement for transplant. That may be partially due to the choice of vasculature that the researchers procured with the graft, but nonetheless they were able to drastically reduce

surgical time (Wei et al., 2017). In addition to a reduction in bleeding and trauma, minimally invasive surgery yields better cosmetic results, which may influence a candidate's readiness to donate (Carbonnel et al., 2020).

Steps involved in Uterine Transplantation

The process of uterine transplantation can be summarized briefly, according to Testa, et al., as follows. First, the successful transplantation of the graft, including perfusion, or blood flow through the grafted vasculature, and the assessment of vital tissue present on the cervix in cervical biopsy to determine if the tissue is accepted by the recipient. Next, a normal menstrual cycle should result, which means that the grafted uterus is responding to the recipient's hormones. Stable immunosuppression, suppression of the recipient's immune system toward the foreign uterus should be maintained. Once immunosuppression is achieved, a fertilized ovum is implanted. After implantation that results in pregnancy, the last step is the successful delivery of a hopefully healthy child. At any of these steps, complications can occur that would result in the failure of the uterine transplant (Testa et al., 2017).

Removing the donor uterus can be done through either laparotomy or laparoscopy. In a 2017 clinical trial on five individuals, the laparotomic removal of the donor uterus is detailed. The hysterectomy performed on the donor, however, is more complicated than a regular hysterectomy, due to the vasculature that needs to be connected to the recipient to allow graft inflow and outflow in the recipient. To allow that, the vascular pedicles, tissues containing the arteries and veins of the donor uterus, were dissected completely. The arterial vascular pedicle of the graft included the uterine artery, which supplies blood flow to the uterus, and a part of the internal iliac artery. The graft uterus was drained by the uterine and utero-ovarian veins, located between the uterus and ovary. A transverse cut was made below the cervix, in order to obtain a cuff that could sufficiently be anastomosed to the upper vagina of the recipient. After removal, arteries were reconstructed, when needed, through microvascular surgery (Testa et al., 2017).

As for the recipient, the external iliac artery and the external iliac vein were dissected and the internal iliac artery patch of the donor was grafted to the external iliac artery of the recipient. For venous outflow, the uterine or utero-ovarian vein, depending on which provided better venous outflow, was sutured to the external iliac vein of the recipient. Once blood flow was reperused, the cervix of the new uterus was connected to the vaginal vault of the recipient. Blood flow was subsequently monitored by a doppler blood flow monitor to assess arterial inflow to the

transplanted uterus. Postoperatively, for the first five days Doppler ultrasounds were performed, cervical biopsy was done on the fifth day, MRI of the uterus was performed to evaluate blood flow, and cervical examination under anesthesia was done to determine if rejection of the transplant tissue occurred. To suppress the immune response of the host to the allograft, immunosuppressive drugs such as thymoglobulin, tacrolimus, mycophenolic acid, and a steroid taper were administered (Testa et al., 2017).

Vasculature Involved

The common iliac artery bifurcates into the internal and external iliac arteries. A branch of the internal iliac artery is the uterine artery, which supplies blood flow to the uterus. Blood flow from the uterus is via the uterine veins, internal iliac veins, inferior vena cava, and to the heart. Figure 1 shows a diagram of the vasculature where blood vessels attached to the allograft are connected slightly differently in the recipient than expected. At point A, the uterine artery, with a branch of the internal iliac from the donor is anastomosed to the external iliac artery, instead of the recipient's own internal iliac artery. At point B, the uterine vein of the donor uterus is attached to the external iliac vein of the recipient, instead of the internal iliac vein.

One of the most difficult parts of uterus transplantation is securing a good venous outflow. In most cases, the uterine veins are used, which often have thin walls, can vary in number, and often are not shown sufficiently in preoperative imaging. During surgery, their dissection can be tedious, can increase the risk of bleeding, and increases surgery time (Testa et al., 2018). Moreover, the uterine vein has multiple branches and is close to the

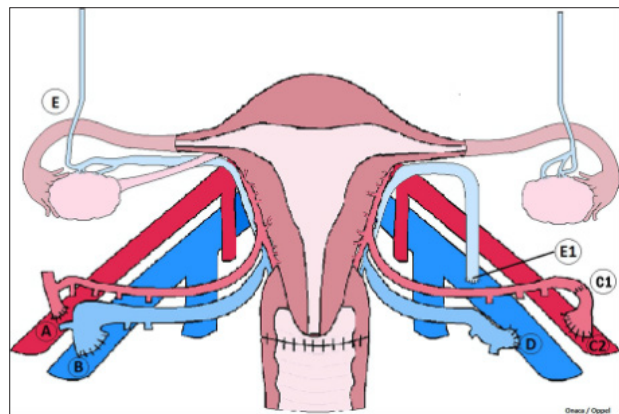


Figure 1. This schematic diagram portrays the blood vessels supplying and draining the allograft uterus. Point A is the anastomosis of the uterine artery to the external iliac artery. Point B is the anastomosis of the donor uterine vein to the external iliac vein (Testa et al., 2017).

Uterine Transplantation Factors Accounting for Success or Failure

ureter, which could result in accidental bleeding or injury to the ureter (Carbonnel et al., 2020). In one 2018 successful trial, researchers sustained an allograft through the utero-ovarian veins alone, without uterine veins. The researchers recommended using the utero-ovarian veins instead of the uterine veins, which are easier to identify, dissect, and provide for safer surgery on the part of the donor. In another clinical trial, the proximal portions of the utero-ovarian veins were dissected as potential extra venous outflow, and ended up being used along with the uterine veins as well, due to the thinness of the uterine veins of the donor (Brannstrom et al., 2020). Further, by using the utero-ovarian veins instead of uterine veins, a robotic laparoscopic approach is more feasible, which will again increase the safety and ease for the donor (Testa et al., 2018). Also, the ovarian veins are more distant from the ureter, so surgeons will not be concerned about inadvertent damage to them (Carbonnel et al., 2020). There can, though, be negative repercussions for the donor associated with using the ovarian veins as venous outflow. In transplant procedures done in both India and China, removal of the ovarian veins required bilateral oophorectomy, removal of the ovaries. The donor women were premenopausal, which increases their risk of morbidity and mortality (Brannstrom et al., 2020). However, using ovarian veins for venous outflow still need to be further researched in the future to determine whether uterus outflow can in all cases be sufficiently maintained using the ovarian veins alone (Carbonnel et al., 2020).

Wait Time Between Transplant and Surgery

Common convention for many of the different uterus transplant trials has been to wait one year between transplantation and attempt at pregnancy, similar to other solid organ transplants. In a 2019 study, for example, embryo transfers were done starting at least 12 months post-transplant, and were done in months 13, 16, 19, and 23, until the last transfer resulted in clinical pregnancy (Chmel et al., 2019). This convention arose out of a recommendation from the American Society of Transplantation which suggested that recipients of organ transplants wait one year between the transplant and conception to decrease any risks that may result, such as acute rejection to the recipient, infection that could harm the fetus, immunotherapy that could potentially be toxic to the fetus, and to be sure that the allograft is functioning properly (Johanesson et al., 2019).

However, women who receive uterus transplants are generally healthy individuals whose surgical recovery should resemble that of any surgical intervention. There is no reason to believe that tissue healing would

be impaired, and immunosuppression does not seem to hinder tissue healing (Testa et al., 2018). Further, a uterine transplant, unlike other organ transplants, is not meant to be a long-term functioning transplant. Its longevity is for about five years and for a maximum of two pregnancies (Johanesson et al., 2019). Some suggest that there is no scientific basis for waiting a year between transplant and embryo transfer, especially because immunosuppression must be terminated as soon as possible, to avoid renal failure, which could be a risk of long-term immunosuppression. Decreased time on immunosuppressants also reduces costs and decreases waiting time for the recipient to give birth to her baby. In their clinical trial, embryo transfer was done before the six month post surgery mark, and yielded successful results (Testa et al., 2018). To provide a groundwork for the amount of time to be waited, researchers laid down conditions to be met in the recipient, which if achieved, should be a signal to begin embryo transfer, as opposed to giving a generalized time recommendation for all uterine transplant procedures. The patient criteria are given in order as follows. First, graft function should be stable. An indication of graft stability would be menstruation, as it is a sign that the foreign uterus is responding to the recipient's hormones. Next, the absence of any acute rejection, which is determined via cervical biopsy. Finally, stable immunosuppression achieved with low teratogenic, or carcinogenic, risk, and the recipient is at low risk for opportunistic infection, which is generally associated with those who undergo transplantation. Once these conditions are met, embryo transfer should begin as soon as possible, even as early as three months post-transplant if the recipient is ready (Johanesson et al., 2019).

Complications in Pregnancy and Post-Operatively

Generally, pregnancies resulting from uterine transplantation do not reach full-term. However, many studies have been successful in which participants have carried close to term. In the first successful clinical study in Sweden, mean delivery for the six patients was at 35 weeks gestation. Besides the difficulty in reaching full term, there are some other pregnancy complications that have arisen. Some patients from the previously mentioned study experienced preeclampsia. It is possible though, that the preeclampsia, preterm delivery, and delivery by cesarean section may be related to the original infertility; MRKH sometimes presents with renal defects, such as having a solitary kidney, which could cause extra stress to the recipient during pregnancy, and has been generally associated with higher risk for preterm delivery, preeclampsia, and cesarean section (Kisu et al., 2018).

Other major complications that have arisen post-operatively in recipients include urinary tract infections, thrombosis, and hematoma. The risk of thrombosis is because the vessels that are anastomosed are generally narrower and can get obstructed more easily than vessels attached in other organ transplants. Hematoma could be the result of inadequate hemostatic processing, or cessation of bleeding. Care must be taken with re-bleeding from capillaries that are unligated or bleeding from the vaginal cuff (Kisu et al., 2018). Also, in one particular clinical study, vaginal stenosis, vesicovaginal fistula, herpes, and cytomegalovirus were complications experienced by some of the recipients. Vesicovaginal fistulae can occur more frequently in patients with MRKH who have a neovagina, which is constructed due to an underdeveloped or absent vagina, and which needs to be separated from the bladder during surgery. This could lead to a fistula, or an opening between the bladder and vagina (Kisu et al., 2018).

Immunosuppressants During Pregnancy

Since the transplanted uterus is from a foreign donor, the recipient needs to be on immunosuppressive drugs to prevent her own immune system from mounting a response against the uterus. There have been different recommendations as to the type of drug, based on trials from both pregnant women on immunosuppressants due to uterus transplants and other organ transplants. The importance here is that the immunosuppressive drug should not be toxic to the developing fetus. Therefore care must be taken to either prescribe immunosuppressants that are not fetotoxic, or at least halt fetotoxic immunosuppressants when the uterus recipient begins embryo transfer. One immunosuppressive drug that has been implicated in spontaneous abortion in the first trimester and congenital abnormalities of the fetus is mycophenolate salts, which come in two different products, mycophenolate mofetil and mycophenolate sodium, that release the compound mycophenolic acid. The FDA classifies this drug as a Category D drug, meaning that there is evidence that it can cause risk to the fetus during pregnancy (Ponticelli et al., 2018). Therefore, if it is used following the transplant, there must be a waiting period afterward before embryo transplant begins. In one uterine transplant trial, mycophenolate mofetil was taken out entirely from the maintenance immunosuppression to decrease the time exposed to toxic medications for the fetus. They were thus able to expedite the waiting time before embryo transfer. Another drug, thymoglobulin, is considered a category C drug, meaning it is currently unknown if risk exists to the fetus. Therefore, there should also be a wait time between pregnancy and usage

of thymoglobulin in immunosuppressive therapy. Other common immunosuppressants such as corticosteroids, azathioprine, and calcineurin inhibitors appear to be safe in doses prescribed for transplant recipients and are not associated with increased risk of congenital defects (Johannesson et al., 2019).

Reasons for Rejection of Transplanted Uterus

Although in some cases there is not a clear reason why the graft failed and rejection occurred, different studies have hypothesized reasons for the difference in outcome. A conclusion was that uterus pathology and venous outflow were largely responsible for three graft failures that occurred. The authors explained that assessment of vasculature preoperatively could be improved. Thus, imaging could be used to eliminate uteri with vasculature that is unsuitable for a uterus transplant. They explain that using a CT angiogram, while helpful in showing arterial blood flow, was not sufficient in their study to tell the length and diameter of veins. This was significant because a large part of the donor hysterectomy surgery time was spent in dissection of the uterine vein, which can taper into thinner tributaries where it joins with the internal iliac vein, even though it may appear satisfactory near the uterine body. The researchers concluded that MRI with venous phase would have been a better choice in imaging to view the uterine veins (Testa et al., 2017). Similarly, the researchers explained that the arterial vasculature was not of the expected quality; in some patients arterial pathology was present. In the preoperative imaging, the vessels appeared patent, however; in the three grafts that failed in their study, there was severe arterial disease present. In one donor specifically there was thickening that resulted in over a fifty percent decrease in luminal size. Additionally, the researchers noted that in the first two of the five patients studied there was a downward kinking of the vein if the anastomosis was to the superior aspect of the host external iliac vein. In the other three patients they switched the venotomy position of the external iliac vein to the medial aspect to avoid kinking. Further, the researchers observed that procuring a patch of the internal iliac with the uterine vein provided a vessel with thicker and stronger walls.

Another potential reason that contributed to the failure of one of the transplants was the variation in size between the large cervix size of the donor and small size of the vaginal vault of the recipient, which made it difficult for vaginal anastomosis. The researchers believed that the limited space, due to the larger cervix size contributed to the graft congestion, poor venous outflow, and pathologies present ultimately resulted in transplant rejection (Testa et al., 2017).

Uterine Transplantation Factors Accounting for Success or Failure

As far as immune-system induced rejection, ostensibly, since the uterus carries a non-self, it would appear that pregnant uterus should have some immune tolerance. However, cervical biopsies have shown rejection in some cases post-operatively. In one transplant study, 13 out of 163 cervical samples taken from seven patients showed mild rejection after transplantation. Steroid therapy helped patients reach remission, yet some developed rejection complications again during pregnancy, which is more difficult to manage and measures need to be developed for the future for treatment-resistant rejection. Some suggest that the contact that the uterus has with the external environment, through the vagina, is responsible for the prospect of rejection of the allograft (Kisu et al., 2018).

Ethical Implications

The practice of uterine transplantation is a subject of great ethical controversy. As a non-life-saving procedure, it differs from other forms of organ transplantation, which are considered essential. However, there are those who categorize it similarly to face, hand, or other vascularized transplants, which though not life-saving transplants, are nonetheless justifiable organ transplants for improving the quality of life of recipients. Additionally, although uterine transplantation is considered an elective treatment, it stands as the only medical treatment for absolute uterine factor infertility. Surrogacy and adoption are options for women with infertility, but for some women they are not adequate substitutes for the experience of pregnancy (Bayefsky and Berkman, 2016).

Once uterine transplantation transitions from an experimental procedure to a common clinical one, there are multiple points that will need to be taken into consideration. There will likely be a shortage of uteri for donation. While there are those who argue that uteri from women who have had hysterectomies should be used to supply organs for uterine transplants, often hysterectomies are done to remove unhealthy uteri, and are done in a way that does not leave the organ fit for transplantation, so those would not be feasible sources of uteri. Uterine transplants must also come with sufficient vasculature, which is generally not removed in an average hysterectomy. Given that there will likely be a greater demand than the supply of uteri, there will need to be a way to prioritize some individuals over others. As far as for other organ transplants, such as heart, kidneys, or lungs, pediatric or younger individuals are generally prioritized over older adults, because adults have experienced childhood, and pediatric patients, if not given the transplant, may never have that experience. In the same vein, it is sensible to say that when prioritizing women for uterine

transplants, women who are of childbearing age should be given precedence over both women who are older and beyond reproductive age and adolescents who have not yet reached childbearing age. However, in choosing between younger and older individuals within the span of child-bearing, women who are nearing the end of their childbearing years should be given priority over younger individuals so that they can have their chance to have children before they age out of their childbearing years, while the younger individuals still have time. "Normal childbearing age" is considered between the ages of 15-49 according to the World Health Organization, and a standard for recipients should be within those limits. A national standard, in limiting the age of recipients, should reflect medical assessment of the surgical and obstetric risks incurred to women of different ages, the risk to the fetus, and the probability of successful pregnancy.

Further, there must also be some sort of child-rearing capacity standard created that potential candidates will demonstrate before allocating a uterus, similar to how women who wish to adopt must meet certain criteria.

In differentiating between women with uterine infertility, different candidates have different needs with regard to treatment. Some need only a transplant, while others may need IVF, egg donation, or sperm donation. It is reasonable to suggest that those with the least interventions necessary to achieve pregnancy should be given priority, in the same vein as choosing candidates for transplantation who are more likely to have successful transplantation (Bayefsky and Berkman, 2016).

Putting aside the controversy associated with candidates for treatment, there is also dispute about the source for donor uteri. Procuring a uterus from a live donor can incur risk to the individual. While there are innovations to the process of securing a uterus, through laparoscopic robotic procedures, as opposed to open laparotomy, advancements will need to be made to decrease the risks for the donor. Also, the advancement of using cadaveric or nonliving donor uteri will be important in fueling the future of uterine transplantation, though it will be a source of contention as to whether a person who has lost all brain function and is considered "brain dead," will be categorized as deceased along with those whose circulatory and respiratory systems have failed.

Conclusion

Uterine Transplantation is a possible radical and innovative surgical option for those who suffer from absolute uterine factor infertility. Many studies have been done world-wide, which have contributed to the available data on the risks and ways to improve the process. While

there is no one factor that contributes to the rejection or success of a uterine transplant, certain factors have been implicated in the reasons for transplant failure or success. Vasculature problems can account for some reasons for rejection, such as sclerotic vessels, or using thin-walled uterine veins that are difficult to dissect and may not provide adequate venous outflow. Adequate imaging should be done to identify vessel pathology and the acceptability of the donor vasculature. The possibility of using the utero-ovarian veins might be a good alternative to the uterine veins, though it can cause the onset of menopause and may increase morbidity in premenopausal women, due to oophorectomy. Also, mismatch in vaginal-cervix size between the donor and recipient may be problematic. Wait time between transplant and embryo transfer and immunosuppressants are other factors to take into account. Advances in using deceased donor uteri, which allows harvesting longer length of vessels, or using live donor uteri procured through laparoscopic robotic assisted hysterectomy can streamline the process. Although a promising treatment for those with absolute infertility, more research needs to be conducted to ensure its safety and to standardize the procedure.

References

- Arian, S. E., Flyckt, R. L., Farrell, R. M., Falcone, T., & Tzakis, A. G. (2017). Characterizing women with interest in uterine transplant clinical trials in the United States: who seeks information on this experimental treatment? *American Journal of Obstetrics and Gynecology*, 216(2), 190–191. doi: 10.1016/j.ajog.2016.11.1028
- Bayefsky, M. J., & Berkman, B. E. (2016). The Ethics of Allocating Uterine Transplants. *Cambridge Quarterly of Healthcare Ethics*, 25(3), 350–365. doi: 10.1017/s0963180115000687
- Brännström, M., Dahm-Kähler, P., Kvarnström, N., Akouri, R., Rova, K., Olausson, M., ... Bokström, H. (2020). Live birth after robotic-assisted live donor uterus transplantation. *Acta Obstetrica Et Gynecologica Scandinavica*. doi: 10.1111/aogs.13853
- Carbonnel, M., Dahm-Kähler, P., Revaux, A., Brännström, M., & Ayoubi, J.-M. (2020). Adapting surgical skills from robotic-assisted radical hysterectomy in cervical cancer to uterine transplantation: a look to an optimistic future! *Journal of Robotic Surgery*. doi: 10.1007/s11701-020-01058-7
- Chmel, R., Pastor, Z., Novackova, M., Matecha, J., Cekal, M., & Fronek, J. (2019). Clinical pregnancy after deceased donor uterus transplantation: Lessons learned and future perspectives. *Journal of Obstetrics and Gynaecology Research*, 45(8), 1458–1465. doi: 10.1111/jog.13992
- Johannesson, L., Wall, A., Putman, J. M., Zhang, L., Testa, G., & Diaz-Garcia, C. (2019). Rethinking the time interval to embryo transfer after uterus transplantation – DUETS (Dallas UtErus Transplant Study). *BJOG: An International Journal of Obstetrics & Gynaecology*, 126(11), 1305–1309. doi: 10.1111/1471-0528.15860
- Kisu, I., Kato, Y., Obara, H., Matsubara, K., Matoba, Y., Banno, K., & Aoki, D. (2018). Emerging problems in uterus transplantation. *BJOG: An International Journal of Obstetrics & Gynaecology*, 125(11), 1352–1356. doi: 10.1111/1471-0528.15230
- Oelschlager, A.-M. E. A., Committee on Adolescent Health Care, North American Society for Pediatric and Adolescent Gynecology, & American College of Obstetricians and Gynecologists' Committee on Adolescent Health Care. (n.d.). *ACOG Committee Opinion No. 728: Müllerian Agenesis... : Obstetrics & Gynecology*. Retrieved January 2018, from https://journals.lww.com/greenjournal/Fulltext/2018/01000/ACOG_Committee_Opinion_No_728_M_llerian.41.aspx
- Ponticelli, C., & Moroni, G. (2018). Fetal Toxicity of Immunosuppressive Drugs in Pregnancy. *Journal of Clinical Medicine*, 7(12), 552. doi: 10.3390/jcm7120552
- Testa, G., Koon, E. C., Johannesson, L., McKenna, G. J., Anthony, T., Klintmalm, G. B., ... Olausson, M. (2017). Living Donor Uterus Transplantation: A Single Centers Observations and Lessons Learned From Early Setbacks to Technical Success. *American Journal of Transplantation*, 17(11), 2901–2910. doi: 10.1111/ajt.14326
- Testa, G., McKenna, G. J., Gunby, R. T., Anthony, T., Koon, E. C., Warren, A. M., ... Johannesson, L. (2018). First live birth after uterus transplantation in the United States. *American Journal of Transplantation*, 18(5), 1270–1274. doi: 10.1111/ajt.14737
- Wei, L., Xue, T., Tao, K.-S., Zhang, G., Zhao, G.-Y., Yu, S.-Q., ... Chen, B.-L. (2017). Modified human uterus transplantation using ovarian veins for venous drainage: the first report of surgically successful robotic-assisted uterus procurement and follow-up for 12 months. *Fertility and Sterility*, 108(2). doi: 10.1016/j.fertnstert.2017.05.039